

ROBOTIC IMRT™ TREATMENT OF PROSTATE CANCER



CyberKnife® Centers of San Diego CyberKnife® Team:

Radiation Oncologist: Donald B. Fuller, M.D.

Medical Physicists: Colin Chu, Ph.D.
George Mardirossian, Ph.D.
M. Munir Muniruzzaman, Ph.D.

CyberKnife Center: CyberKnife Centers of San Diego

DEMOGRAPHICS

Sex: Male
Age: 63 years old
Histology: Prostatic Adenocarcinoma, Stage T3a (MRI), Gleason Score 4 + 5 = 9

CLINICAL HISTORY

Referred by: Community Urologist
Past Medical History: Benign prostatic hypertrophy
Medications: Doxazosin mesylate (alpha blocker) 8 mg every day

Case History

This 63-year-old man presented with a prostate-specific antigen (PSA) level that had increased from 5.0 ng/ml to 7.0 ng/ml over two years. Prostate biopsy revealed Gleason score 4 + 5 = 9 adenocarcinoma, stage T1c by digital rectal exam and stage T3a by staging MRI scan (which revealed extension into the right neurovascular bundle). Dynamic contrast-enhanced MRI (DCE-MRI) images revealed substantial bilateral peripheral zone involvement. There was no evidence of metastatic disease on bone scan, abdominopelvic CT or pelvic MRI evaluation. Based on these findings the patient was staged as T3aNOMO and classified as having high-risk, localized prostate cancer.

CyberKnife® Treatment Rationale

The patient's high Gleason score and evidence of extension outside the prostate indicated a substantial risk of involvement of the seminal vesicles and suggested the need to increase the GTV-to-CTV margin expansion and include the seminal vesicles in his treatment plan. Given this larger treatment volume, a more conventional fractionation scheme (as opposed to that employed for accelerated hypofractionation treatments) was chosen to better spare the surrounding tissues, including the bladder and rectum, from radiation injury. The CyberKnife® System enabled the use of robotic intensity-modulated radiotherapy (RIMRT) for this patient. Continual image guidance and a robot-mounted linear accelerator, combined with modulation of the beam using the Iris™ Variable Aperture Collimator, allows the CyberKnife System to track and correct for prostate movements while delivering a custom-modulated dose distribution within the prostate. Conventional, gantry-based IMRT systems can not actively correct for prostate movement and therefore require a larger CTV→PTV margin expansion to account for intrafraction prostate motion. With the CyberKnife System, margins can be significantly reduced while delivering a dose distribution that conforms maximally to the PTV. The system can also be used to precisely and selectively deliver a higher dose to involved areas within and adjacent to the prostate that are identified by sophisticated imaging methods such as DCE-MRI.

TREATMENT DETAILS

Target Volume:	186.7 cm ³	Fractions:	28 fractions
Imaging Technique(s):	CT, DCE- and T2-weighted MRI	Path Template:	Prostate Short Path
Rx Dose & Isodose:	70 Gy to the 70% isodose line, with simultaneous integrated boosting within the prostate	Tracking Method:	Fiducial Tracking
		Collimator:	Iris™ Variable Aperture Collimator

Treatment Planning and Delivery

Five fiducials were implanted into the prostate prior to the planning CT and MRI scans. The treatment plan was constructed based on fused CT/MRI scans. For both image sets, a Foley catheter was used to identify the urethra. The rectum was emptied by administration of Fleets enemas.

Treatment was based on the Cleveland Clinic IMRT regimen.^{1,2} A total of 70 Gy in 28, 2.5-Gy fractions was delivered to a CTV comprised of prostate plus seminal vesicles with 3-mm margins anterior and posterior, 5 mm lateral (see Figure 2). Due to demonstrated sub-millimeter prostate targeting accuracy, there was no significant additional CTV→PTV expansion.³ The prescription dose was delivered to the 70% isodose line, providing > 95% PTV coverage. The dose distribution was modified from the Cleveland Clinic regimen to provide simultaneous integrated boosting (SIB) to a mean dose of > 86 Gy to areas of gross tumor involvement within the prostate, as shown on DCE-MRI. The resulting 2-Gy/fraction relative biological effectiveness (RBE) exceeded 100 Gy, based on an α/β ratio of 3 Gy.

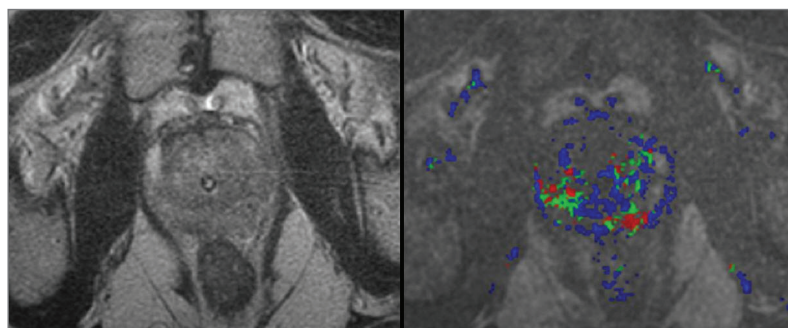


Figure 1. MRI (left panel) of the prostate; MRI with DCE perfusion image mapping of the DIL shown in red and green (right panel).

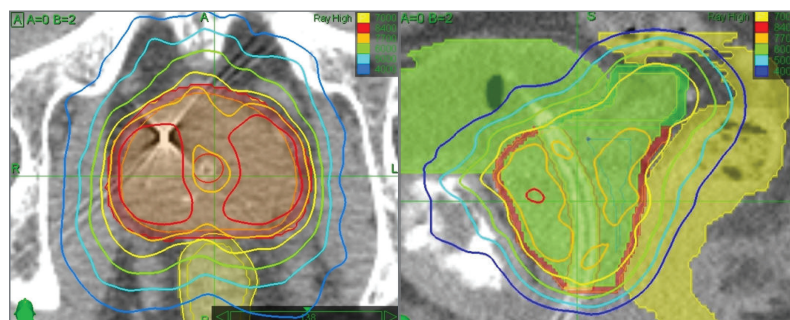


Figure 2. Axial and sagittal planning images. The prescription isodose line (70 Gy) is indicated by the yellow isodose line. High-dose regions (84 Gy, red; 77 Gy, orange) correspond to the DIL shown in Figure 1.

This table depicts relative dosimetry for the current case and that reported for the Cleveland Clinical Series.

Dosimetric parameter	Current case	Cleveland Clinic ^{1,2}
Mean prostate dose	80 Gy	75 Gy
Mean urethra dose	75 Gy	Not reported
Rectal V70Gy	1.7 cc	8 cc
Bladder V70Gy	4 cc	7 cc

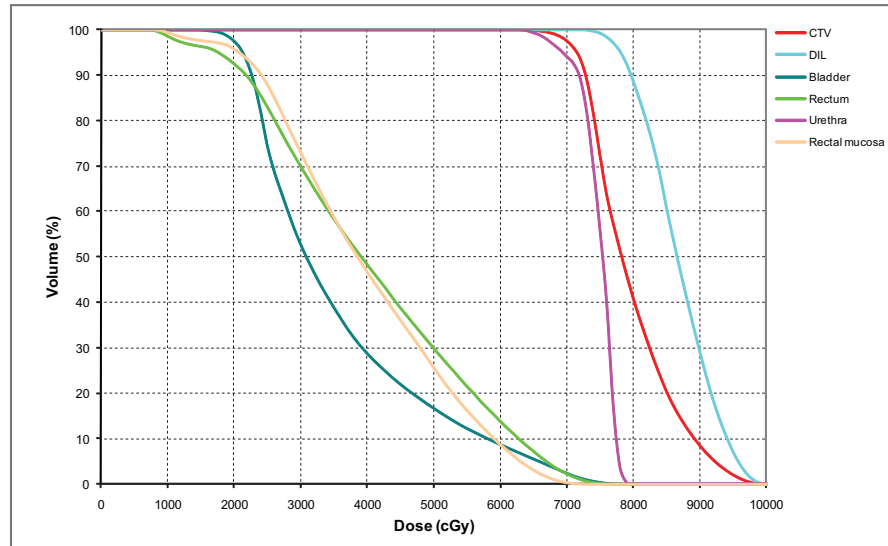


Figure 3. Dose volume histogram (DVH) illustrating CTV coverage to 70 Gy, with DIL dose escalation to a mean dose of approximately 86 Gy, with limitation of urethra, bladder and rectum doses comparable to the Cleveland Clinic regimen.^{1,2}

Outcome and Follow-Up

- During treatment the patient reported fatigue and increased urinary frequency. Urinary frequency almost completely returned to pre-treatment baseline level following an increase in doxazosin dosage to 12 mg/day (compared with 8 mg/day pre-treatment).
- The patient experienced no symptoms of rectal toxicity at any point during his treatment course
- At the 3-month follow-up his urinary symptoms improved, indicated by a decrease in IPSS score from 20 before treatment to 14, on a continued doxazosin dose of 12 mg per day. His fatigue had completely resolved and he remained free of rectal symptoms
- His 3-month PSA value decreased to 0.9 ng/ml (from 7.0 ng/ml just before treatment)

Conclusion and CyberKnife® Advantages

- CyberKnife® RIMRT enabled delivery of conventionally fractionated treatment to the PTV comprised of the prostate and seminal vesicles, while simultaneously delivering accurate dose escalation to the DIL within the prostate and maximally sparing surrounding critical tissues
- The ability to track and correct for prostate movements during treatment reduced uncertainty in target location, thereby allowing smaller treatment volumes than those possible using conventional IMRT systems

CYBERKNIFE CENTERS OF SAN DIEGO

CyberKnife Centers of San Diego opened their first office in a patient-friendly, central San Diego location in June of 2006. To serve increasing demand from patients and referring physicians alike, the second CyberKnife Centers of San Diego office was opened in North Coastal San Diego County in November 2007. Prostate and lung cancer have been the two most prevalent CyberKnife applications to date in this practice, with the physicians and staff believing CyberKnife radiosurgery to represent paradigm-shifting technology for these and other cancer indications.

To contact a CyberKnife Center of San Diego, call 858-505-4100 or 760-230-6706.

References

1. Mohan DS, Kupelian PA, Willoughby TR. Short-course intensity-modulated radiotherapy for localized prostate cancer with daily transabdominal ultrasound localization of the prostate gland. *Int J Radiat Oncol Biol Phys* 2000;46:575-580.
2. Kupelian PA, Willoughby TR, Reddy CA, et al. Hypofractionated intensity-modulated radiotherapy (70 Gy at 2.5 Gy per fraction) for localized prostate cancer: Cleveland Clinic experience. *Int J Radiat Oncol Biol Phys* 2007;68:1424-1430.
3. Xie Y, Djajaputra D, King CR, et al. Intrafractional motion of the prostate during hypofractionated radiotherapy. *Int J Radiat Oncol Biol Phys* 2008;72:236-246.